

- 42 Orlic P, Vukas D, Drescik I, Ivancic A, Blečić G, Budiselić B, et al. Vascular complications after 725 kidney transplantations during 3 decades. *Transpl Proc* 2003;35:1381–4.
- 43 Mehrabi A, Golriz M, Maier J, Fonouni H, Garoussi C, Hafezi M, et al. Long-Term follow-up of kidney transplant recipients with polycystic kidney disease. *Exp Clin Transpl* 2015;13:413–20.

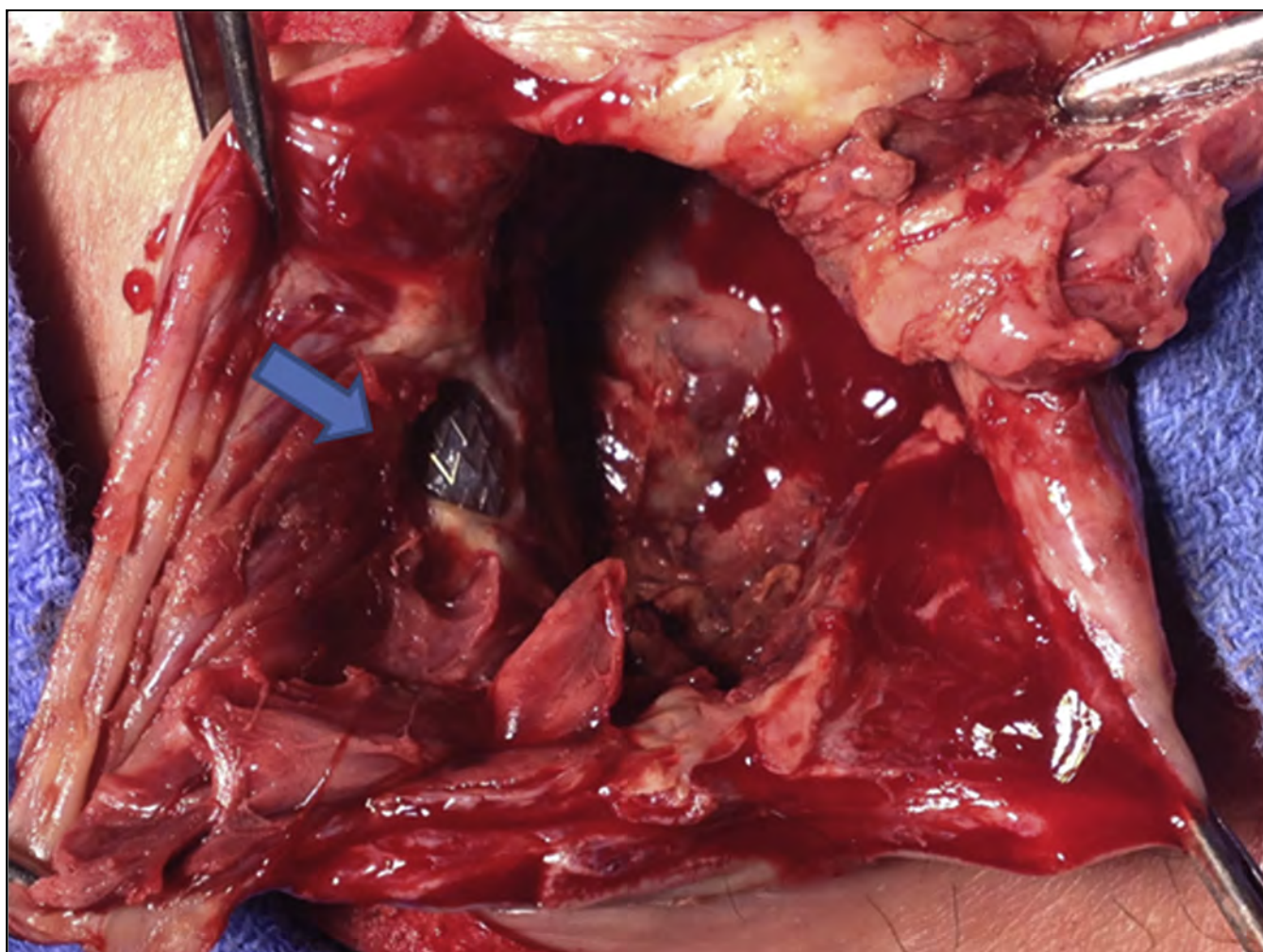
Eur J Vasc Endovasc Surg (2019) 57, 149

COUP D'OEIL

A Stent Graft Visualised Through an Infected Haemodialysis Graft Pseudoaneurysm

Spyros I. Papadoulas^{*}, Stavros K. Kakkos

Department of Vascular Surgery, University of Patras Medical School, Patras, Greece



A 64 year old male presented with two needlestick pseudoaneurysms of a brachio-axillary PTFE haemodialysis graft; these were repaired by endovascular means using 7 × 40 mm and 7 × 60 mm Covera stent grafts (Bard, Tempe, AZ, USA) with peri-operative teicoplanin antibiotic prophylaxis. Two weeks later he presented with infection of the largest (5 cm) pseudoaneurysm, which was managed by partial graft excision. Intra-operatively the pseudoaneurysm was incised and pus drained. The stent graft was visualised through the graft defect (arrow). The aneurysm sac, part of the graft, and stent graft were excised. Culture results were normal. The wound healed by secondary intention, after a six week vancomycin/ciprofloxacin antibiotic course.

^{*} Corresponding author. Department of Vascular Surgery, University Hospital of Patras, Patras, 26504, Greece.

E-mail address: spyros.papadoulas@gmail.com (Spyros I. Papadoulas).

1078-5884/© 2018 European Society for Vascular Surgery. Published by Elsevier B.V. All rights reserved.

<https://doi.org/10.1016/j.ejvs.2018.10.005>